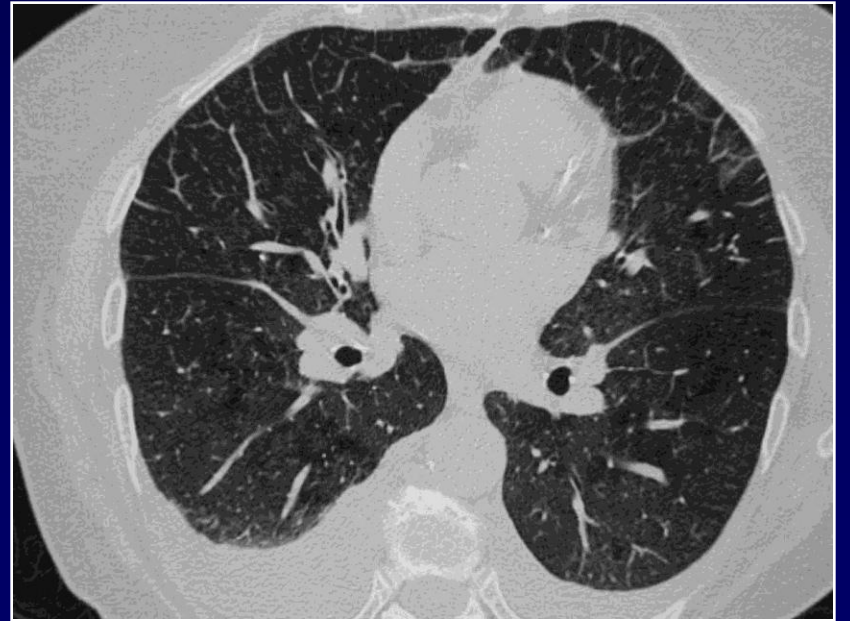
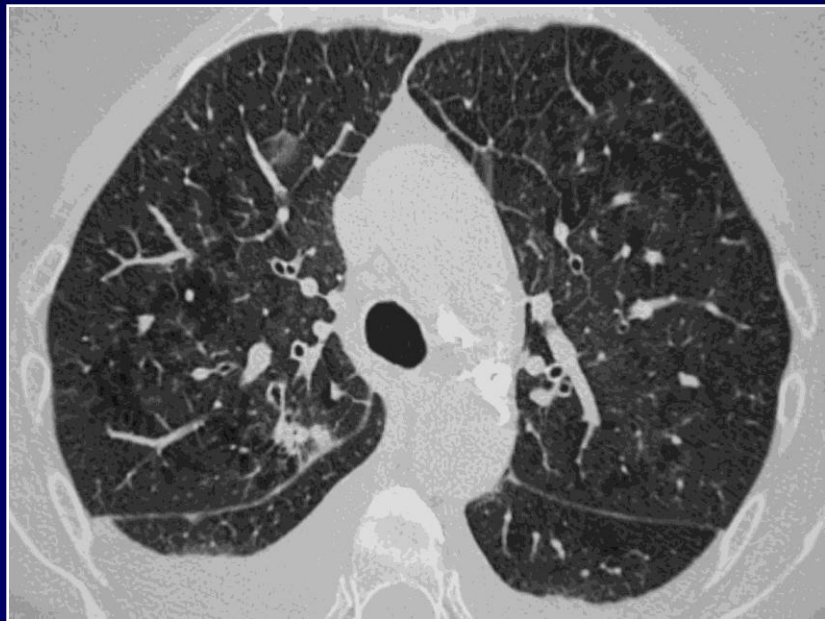
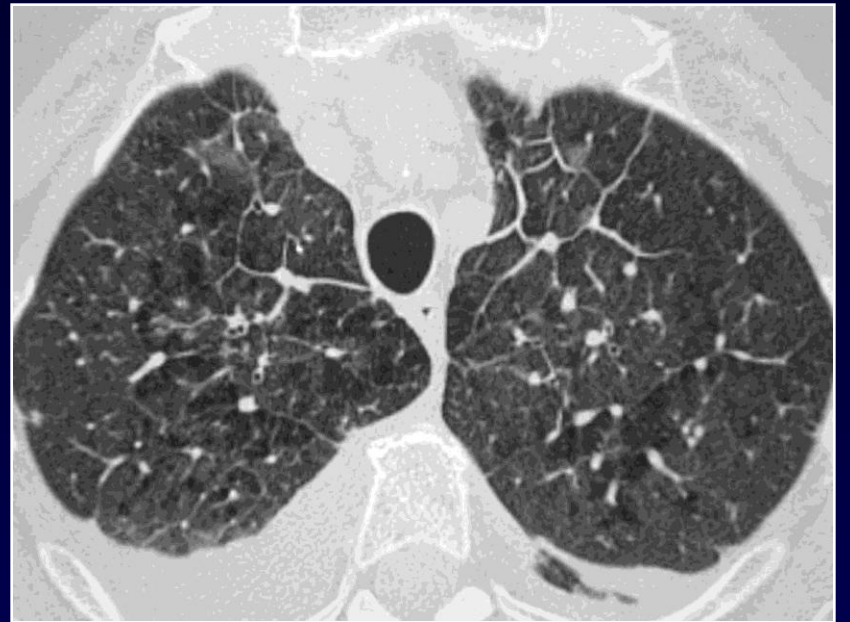
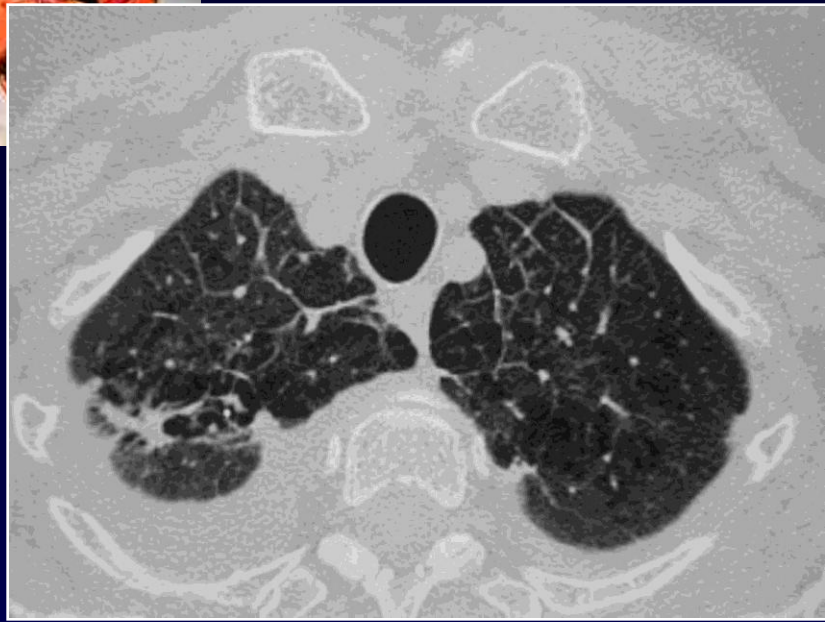
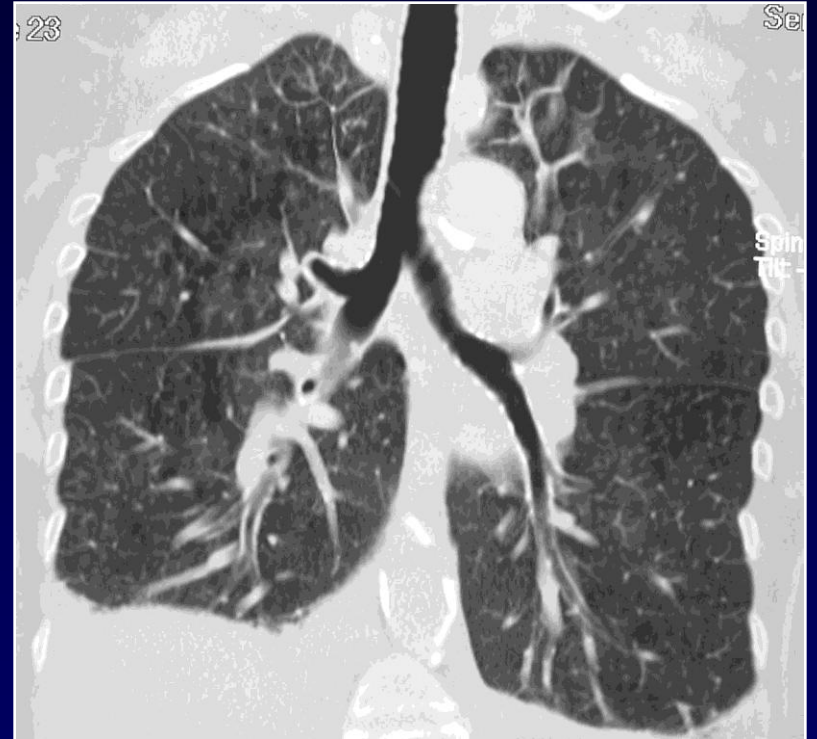
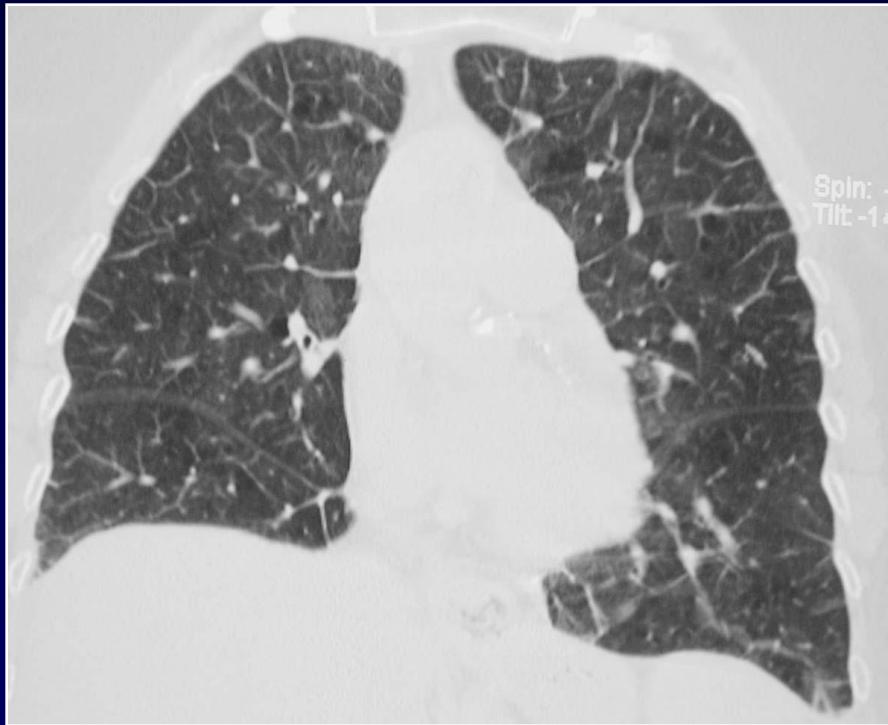


**J. GIRON**

**Femme de 74 ans**

**Myélome avec amylose rectale**







**Diagnostic ?**



# Amylose septale